

October 15, 2018

## Important Update to Field Safety Notice

### Nellix® EndoVascular Aneurysm Sealing System

Dear Physician,

Ongoing monitoring of field experience data has indicated that additional factors linked to the adequacy of the technical procedure may place patients at higher risk of experiencing a Nellix-related complication. This notice provides additional procedural and surveillance recommendations for such patients and is for information only. **No product return is required.** The Regulatory Agency of your country has been notified of this communication.

This notification is an update to the Field Safety Notice (FSN) distributed in October 2016 regarding the Nellix EndoVascular Aneurysm Sealing System (“Nellix System”). This emphasized refined indications for use and focused on the *anatomical criteria* for determining whether a patient was at risk for experiencing a Nellix-related complication. (Reference Attachment 1).

#### **Procedural Criteria Impacting Nellix Success**

The latest data indicates that the extent of Endobag contact with non-aneurysmal tissue proximally and distally has implications for patient outcomes. As such, the following *procedural factors* are important contributors to a successful outcome:

- Minimum of 10mm acquired proximal and distal seal
- Avoidance of low / misaligned stent placement

Considering these elements, Endologix has determined the criteria list in Table 1 must be met post-procedurally in order for a procedure to be considered technically adequate. A detailed description of each of these procedural elements is provided in Attachment 2 with information regarding calculation of the seal zones in Attachment 3. The IFU will be updated to include this information.

Table 1: Post-Procedural Requirements

Acquired Distal Seal* $\geq$ 10 mm
Acquired Proximal Seal* $\geq$ 10 mm
Lowest stent within 10 mm of the lowest renal artery
<i>*Note: The acquired proximal and distal seal zones are defined by the extent that the EndoBag is in contact with the aortic or iliac wall. Further information to calculate this is included in Attachment 3.</i>

#### **Definition of At Risk Patients**

Patients previously implanted with the device that met the refined anatomical indications for use have been categorized as On-Target. Patients not meeting these criteria have been categorized as Off-Target with an increased risk of experiencing a Nellix-related complication, for which enhanced surveillance has been recommended. This distinction had been limited to anatomical factors. However, based on the most recent

evaluation of the available clinical data, procedural adequacy is also critical in determining whether a patient is at risk of experiencing a Nellix-related complication.

### **Patient-Tailored Surveillance Recommendations**

As described in previous updates, all patients require life-long, regular follow-up to assess the performance of their endovascular implant. Physicians should evaluate patients on an individual basis and prescribe their follow-up relative to the needs and circumstances of each individual patient. This is in line with personalized surveillance regimens discussed in the clinical practice guidelines published by the Society of Vascular Surgeons (ESVS).<sup>1,2</sup> As a minimum:

1. **All asymptomatic patients should continue on at least annual follow-up, and this is particularly important for those who would now be considered Off-Target according to the refined IFU for both anatomical and/or procedural criteria.**
2. Enhanced clinical surveillance including contrast-enhanced CT scan (*If renal complications or other factors preclude the use of image contrast medium, abdominal radiographs and duplex ultrasound may provide similar information*) should be:
  - a. Undertaken for patients with specific clinical findings (i.e., migration, endoleaks, or enlarging aneurysms)
  - b. Considered for patients at higher risk of graft-related complications, specifically those who are determined not anatomically and procedurally On-Target
3. Additional secondary endovascular interventions (reference Attachment 4; previously provided via the October 2017 FSN Update) or conversion to standard open surgical repair should be considered for patients continuing to experience migration, significant endoleaks, and/or enlarging aneurysms during post-operative follow up.

### **Supporting Data from US IDE Study:**

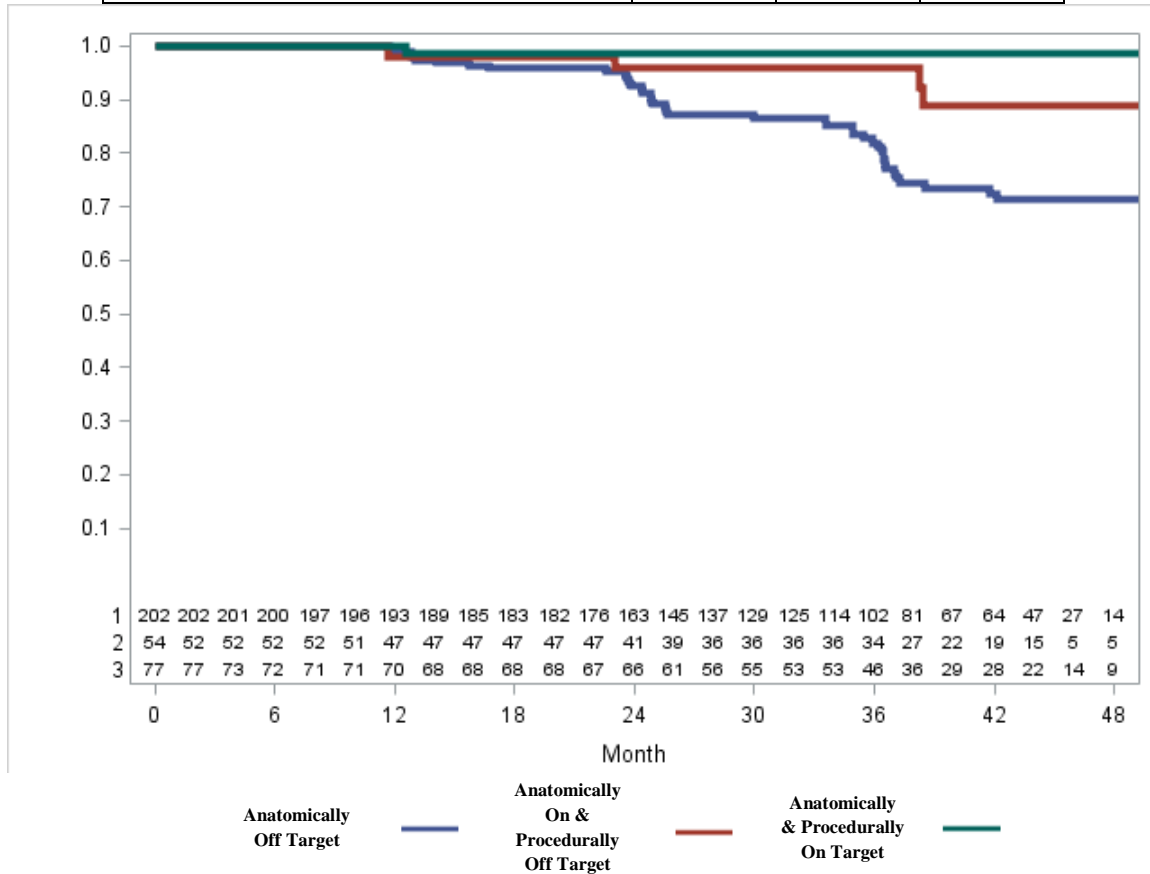
Utilizing data from the US IDE study as of June 14, 2018, **Figure 1** through **Figure 3** provide the freedom from rates for the various patient categories and demonstrates the importance of a Nellix patient meeting both the refined anatomical criteria and procedural criteria.

---

<sup>1</sup> Chaikof, Elliot L., et al. "The Society for Vascular Surgery Practice Guidelines on the Care of Patients with an Abdominal Aortic Aneurysm." *Journal of Vascular Surgery*, vol. 67, no. 1, Jan. 2018, pp. 2–77.e2.

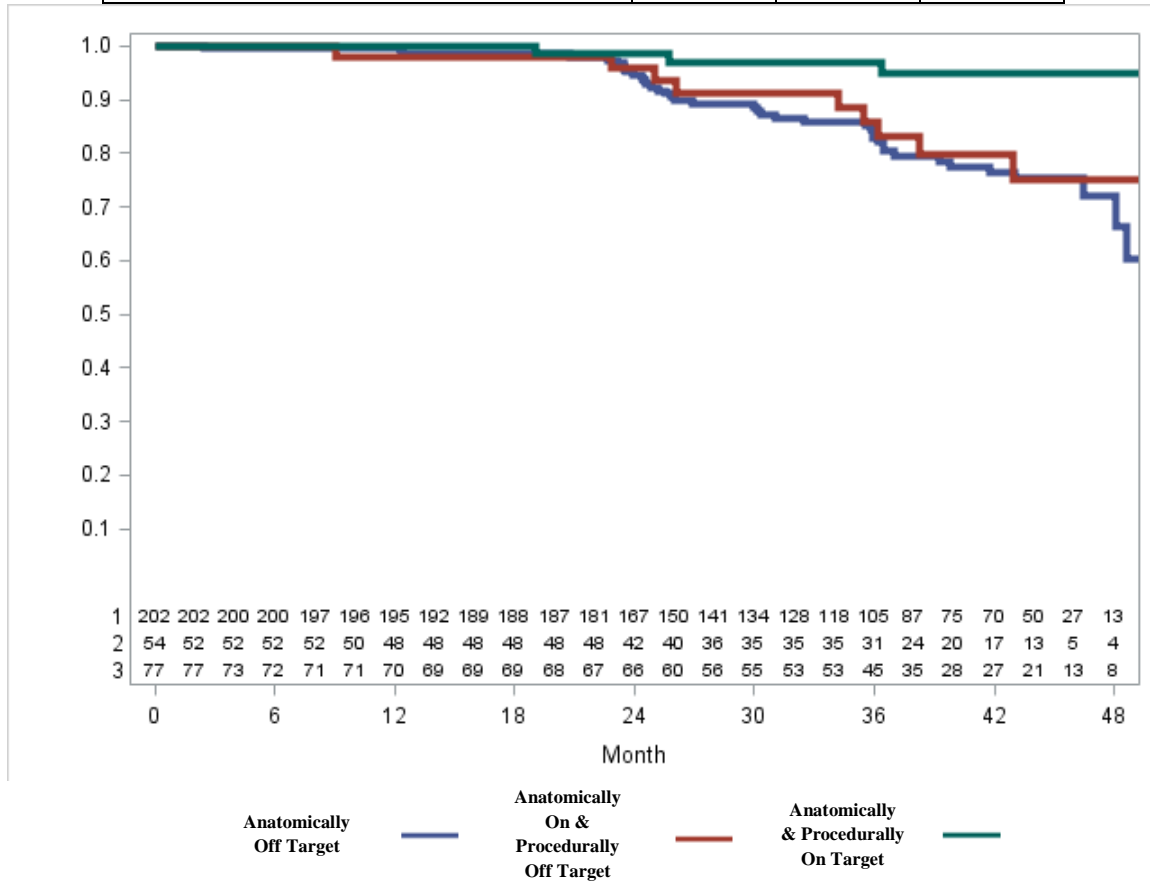
<sup>2</sup> Moll, F.I., et al. "Management of Abdominal Aortic Aneurysms Clinical Practice Guidelines of the European Society for Vascular Surgery." *European Journal of Vascular and Endovascular Surgery*, vol. 41, 2011, pp. S1–S58.

<b>Freedom from Migration &gt; 10mm</b> <i>(Corresponding line on x-axis)</i>	<b>12 Months</b>	<b>24 Months</b>	<b>36 Months</b>
Anatomically & Procedurally On-Target (3)	100%	98.6%	98.6%
Anatomically On-Target & Procedurally Off-Target (2)	98.0%	95.9%	95.9%
Anatomically Off-Target (1)	99.5%	92.5%	82.0%



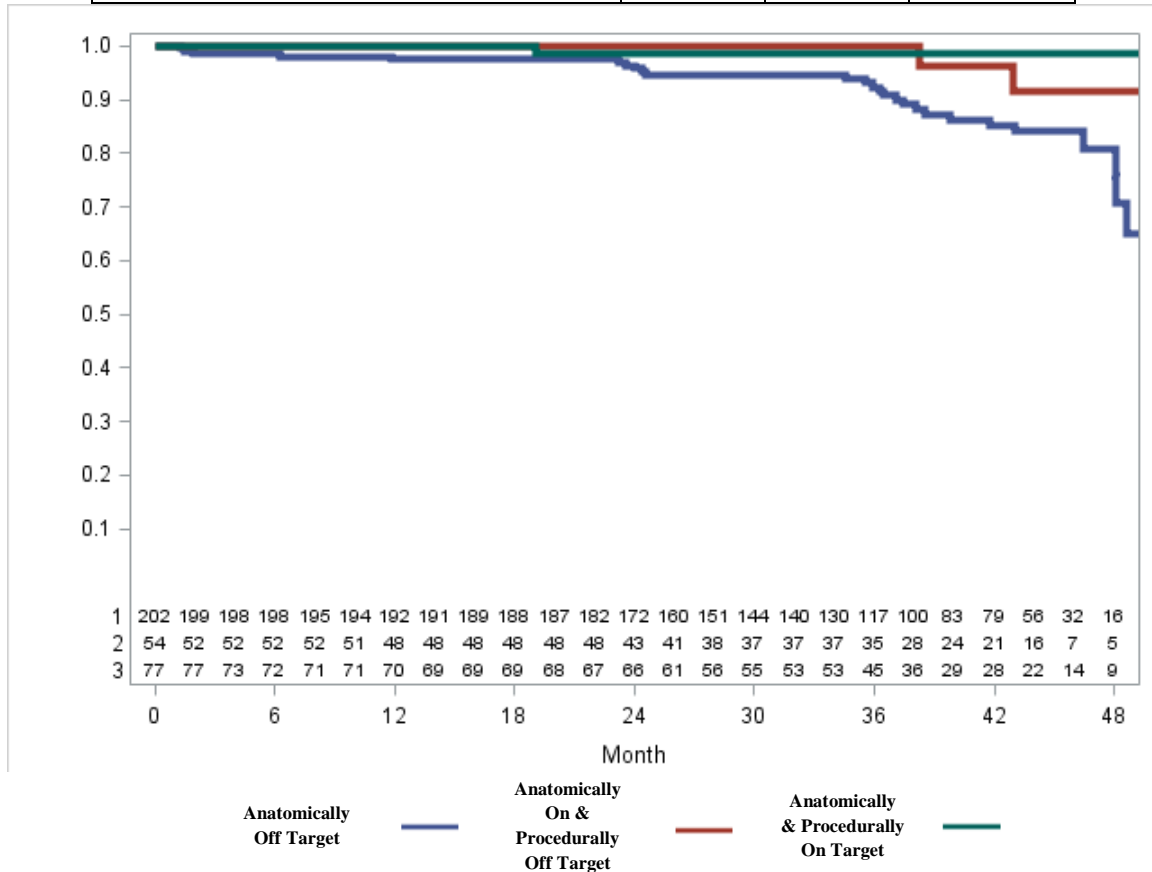
**Figure 1: Freedom from Migration >10mm**

<b>Freedom from Aneurysm Enlargement</b> <i>(Corresponding line on x-axis)</i>	<b>12 Months</b>	<b>24 Months</b>	<b>36 Months</b>
Anatomically & Procedurally On-Target (3)	100%	98.6%	96.9%
Anatomically On-Target & Procedurally Off-Target (2)	98.0%	96.0%	86.0%
Anatomically Off-Target (1)	99.5%	94.6%	82.8%



**Figure 2: Freedom from Aneurysm Enlargement**

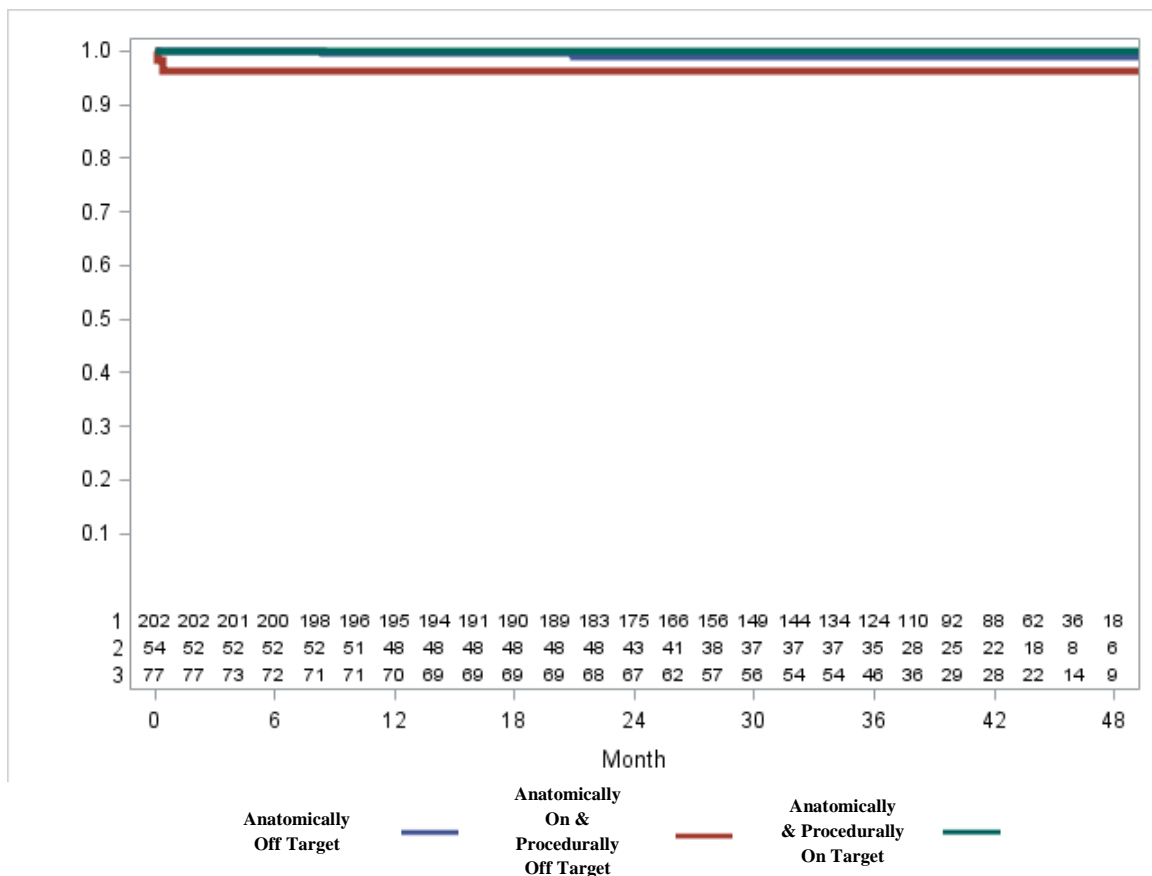
<b>Freedom from Type Ia Endoleak</b> <i>(Corresponding line on x-axis)</i>	<b>12 Months</b>	<b>24 Months</b>	<b>36 Months</b>
Anatomically & Procedurally On-Target (3)	100%	98.6%	98.6%
Anatomically On-Target & Procedurally Off-Target (2)	100%	100%	100%
Anatomically Off-Target (1)	97.5%	96.4%	92.4%



**Figure 3: Freedom from Type Ia Endoleak**

As is demonstrated in **Figure 4** below, there exists a low rate of aneurysm-related mortality within the IDE trial for any Off-Target patient relative to those patients who are both anatomically and procedurally On-Target. This has been identified from the stringent follow-up protocol required as part of the trial and highlights the importance of adequate patient surveillance commensurate to the risk category a patient presents (i.e., On or Off-Target).

<b>Freedom from Aneurysm Related Mortality</b> <i>(Corresponding line on x-axis)</i>	<b>12 Months</b>	<b>24 Months</b>	<b>36 Months</b>
Anatomically & Procedurally On-Target (3)	100	100	100
Anatomically On-Target & Procedurally Off-Target (2)	96.3	96.3	96.3
Anatomically Off-Target (1)	99.5	99.0	99.0



**Figure 4: Freedom from Aneurysm Related Mortality**



Endologix International Holdings B.V.  
Burgemeester Burgerslaan 40  
5245 NH, Rosmalen, NL  
+31 88 116 91 01  
endologix.com

We will continue to monitor the clinical experience with the Nellix System, listen to physician feedback, and update you with any important information that we learn through our post-market surveillance programs. We appreciate your review of this notification and request that you share it within your organization as appropriate. If you have any questions regarding the content of this notification, please contact your Endologix representative or Endologix Customer service at +31 88 116 91 01.

The Nellix System represents a novel endovascular aneurysm sealing (EVAS) therapy that is differentiated from conventional endovascular aneurysm repair (EVAR) modalities. We are continuing to monitor the clinical experience with the Nellix System and remain committed to sharing relevant information that may impact patient safety or outcomes.

Yours Sincerely,

A handwritten signature in blue ink that reads "Matt Thompson".

Matt Thompson, MD  
Chief Medical Officer

### Attachment 1: Reminder of IFU Updates

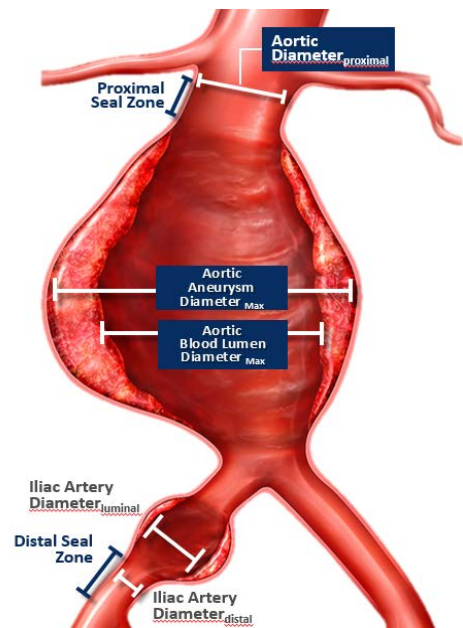
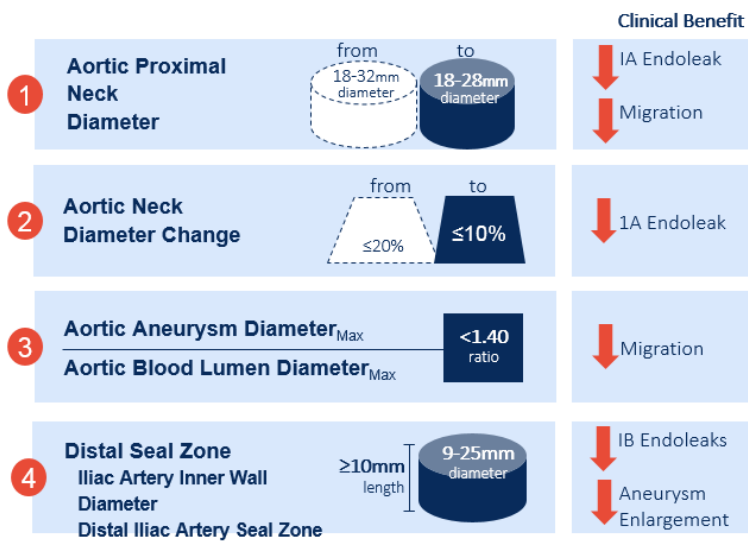
In the October 2016 FSN, Endologix communicated that it was updating the Nellix System Instructions for Use (IFU) with respect to:

1. The indications for use
2. Patient selection criteria
3. Procedural best practices

These updates were made to reduce the potential clinical risks of:

1. Migration
2. Type I endoleaks
3. Aneurysm enlargement

Although the procedural best practices were incorporated in the previous FSNs, emphasis was placed on the refined indications for use and focused on the anatomical criteria captured in **Figure 5** for determining if a patient is at risk for experiencing a Nellix-related complication.



**Note:** The distal iliac artery seal zone diameter in the Nellix 3SQ+ version of the device is 9-20mm

**Figure 5: Updated anatomical factors**



Furthermore, the following patient selection criteria and procedural best practices were previously communicated in the October 2016 FSN:

#### **Updated Patient Selection Criteria**

Patients exhibiting the following key anatomic elements may be at risk for implant displacement, endoleaks, and/or aneurysm enlargement:

- Anatomies outside of the respective, specific criteria defined as part of the indications for use
- Narrow aortoiliac bifurcation not suitable for balloon-expandable stent deployment
- Formation of thrombus and/or calcium at the arterial implantation sites, specifically the proximal aortic neck and distal iliac artery interface (i.e., sealing zone)

#### **Updated Procedural Best Practices**

- Select patients with appropriate anatomies that are within the labeled indications for use and updated patient selection criteria outlined above.
- To maximize EndoBag seal:
  - Position the bottom of the first Nellix stent element as close as possible to the ostium of the most caudal renal artery in healthy proximal anatomy
  - Position the distal portion of the EndoBag in the iliac artery to achieve at least 10mm of seal in healthy distal anatomy
- The positioning of both Nellix implants must be maintained for the duration of the procedure
- To expand the Nellix stents, inflate the Nellix catheter balloons to nominal pressure (7 ATM) during stent deployment prior to pre-fill
- The Nellix catheter balloons need to be inflated to nominal pressure (7 ATM) during polymer cure
- Confirm proximal and distal seal, utilizing multiple angiographic views, prior to removing both Nellix nosecones

## ***Attachment 2: Post-Procedural Requirements***

As discussed above, the following procedural factors have been identified as contributors to whether or not a patient is at risk for experiencing a Nellix-related complication:

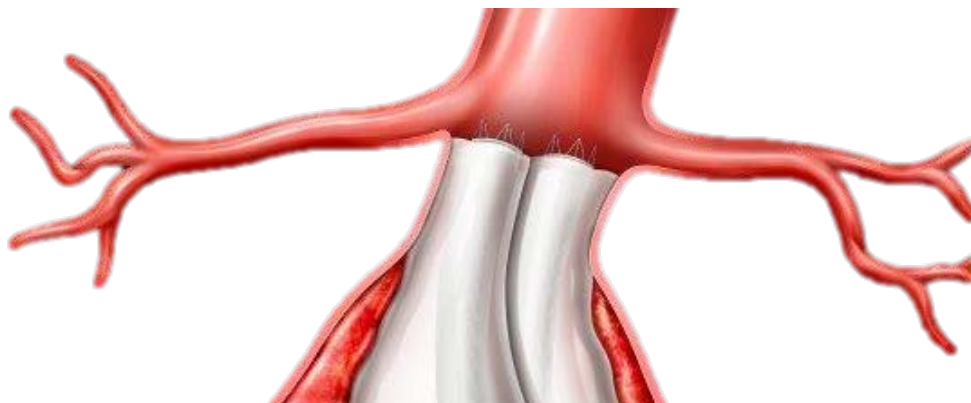
- Lack of acquired proximal or distal seal
- Low/misaligned stent placement

### ***Acquired Proximal or Distal Seal***

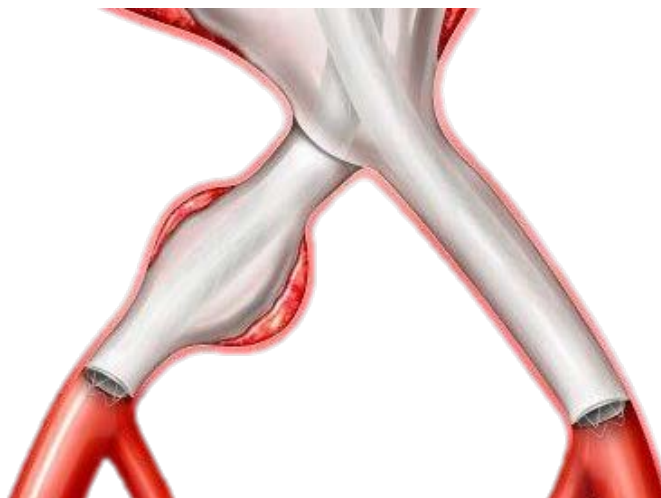
Although the October 2016 FSN included procedural best practices, the importance of ensuring an adequate procedure in line with the previous IFU updates made to the patient selection criteria and procedural best practices has become more apparent. Specifically, the acquired seal zones include where the EndoBag is in contact with the aortic wall. In order to maximize the EndoBag seal, the updated IFU instructs the physician to:

- Position the bottom of the first Nellix stent element as close as possible to the ostium of the most caudal renal artery in healthy proximal anatomy
- Position the distal portion of the EndoBag in the iliac artery to achieve at least 10mm of seal in healthy distal anatomy

**Figure 6 and Figure 7** show examples of the acquired proximal and distal seal when the procedural best practices are followed. **Figure 8** provides examples of low stent placement and misaligned stents.



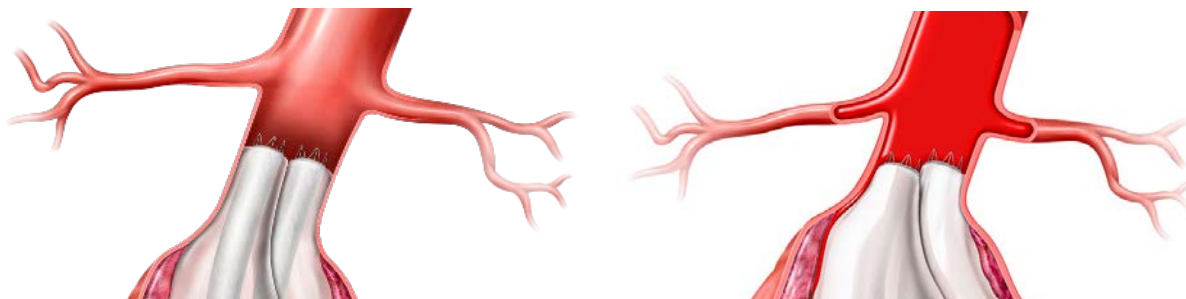
**Figure 6: Example of acquired proximal seal (where the EndoBag is in contact with the aortic wall)  $\geq 10$ mm**



**Figure 7: Example of acquired distal seal (where the EndoBag is in contact with the aortic wall)  $\geq 10\text{mm}$**

### ***Low/Misaligned Stent Placement***

The acquired seal zones include where the EndoBag is in contact with the aortic wall. Since low stents do not maximize the healthy neck available, the acquired EndoBag seal is often less than is required. Additionally, in the event of misaligned stents, the EndoBag does not contact the aortic wall within the entire circumference until the bottom Nellix stent. As such, misaligned stents acquire a smaller EndoBag seal than is initially perceived.

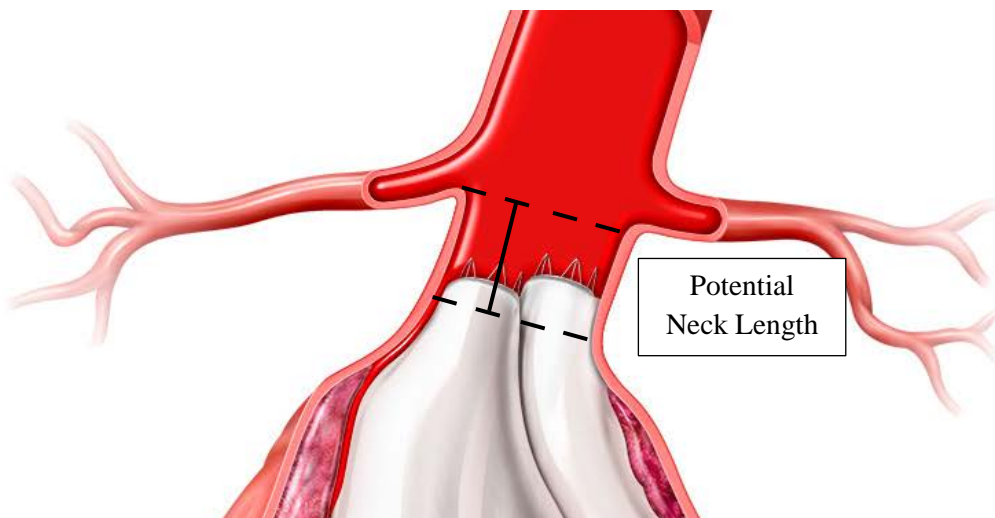


**Figure 8: Example of low stent placement (left) and misaligned stents (right)**

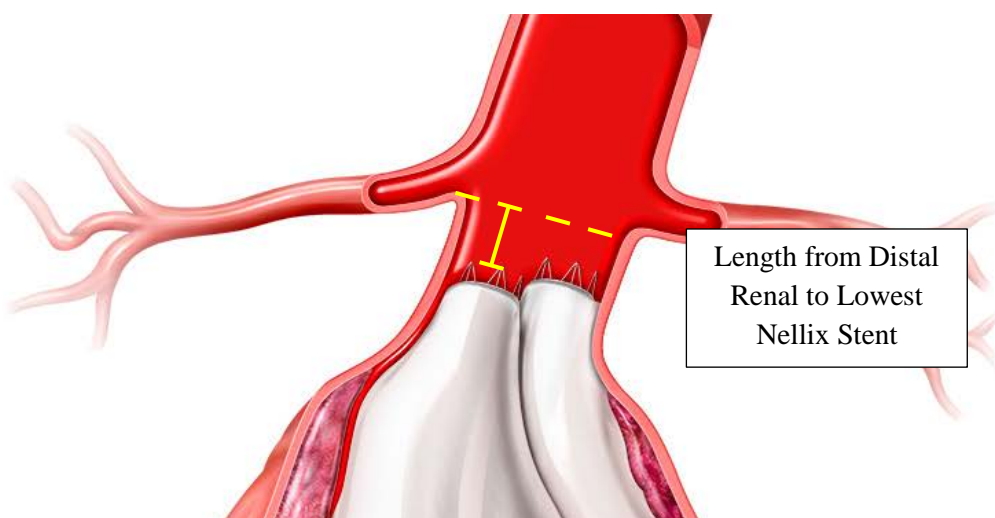
***Attachment 3: Example Calculation of the Acquired Proximal Seal***

The Acquired Proximal Seal is a composite of the following four variables, calculated in the first available post-operative scan:

1. The Potential Neck Length (as defined in the IFU as the length from the lower margin of the most-caudal renal artery to a point distally where the lumen diameter change is 10%, after which point it is considered the start of the aneurysm sac).
2. The length from the distal renal artery to the top of the right Nellix metal stent
3. The length from the distal renal artery to the top of the left Nellix metal stent
4. 4mm: The length from the top of the Nellix metal stent to the top of the EndoBag (i.e. EndoBag shelf)



**Figure 9: Example of the “Potential Neck Length” measurement after initial implantation**




**Figure 10: Example of the “Distance to the Lowest Stent” measurement (i.e. length from the distal renal artery to the top of the lowest Nellix stent)**

The Estimated Proximal Seal is then calculated by subtracting the distance to the lowest stent from the available neck length.

$$\text{Estimated Proximal Seal} = \text{Potential Neck Length} - \text{Distance to the Lowest Stent}$$

The EndoBag is attached to the stent such that the EndoBag shelf aligns with the bottom of the first stent cell segment, ~4mm below the top of the stent (**Figure 11**).

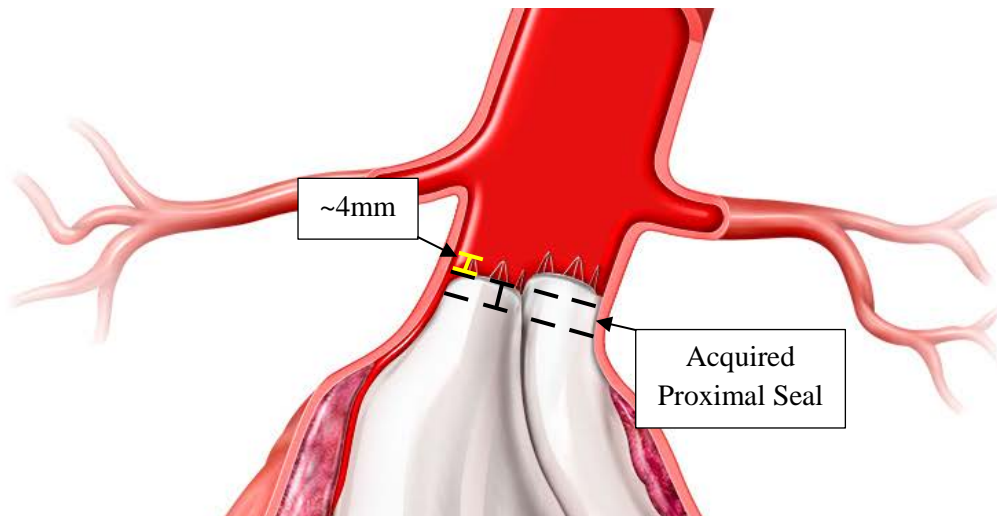


**Figure 11: Attachment of the EndoBag to the stent on the proximal end of the implant**

As a result, ~4mm is subtracted from the Estimated Proximal Seal variable to approximate where the shelf of the polymer-filled EndoBag begins in order to obtain the Acquired Proximal Seal calculation.

Finally, the Acquired Proximal Seal is calculated by subtracting 4mm from the Estimated Proximal Seal.

$$\text{Acquired Proximal Seal} = \text{Estimated Proximal Seal} - 4\text{mm}$$



**Figure 12: Example of the ~4mm between the top of stent and the EndoBag attachment (i.e. bottom of the first stent cell segment) (top, yellow) and the “Acquired Proximal Seal” (bottom, black)**

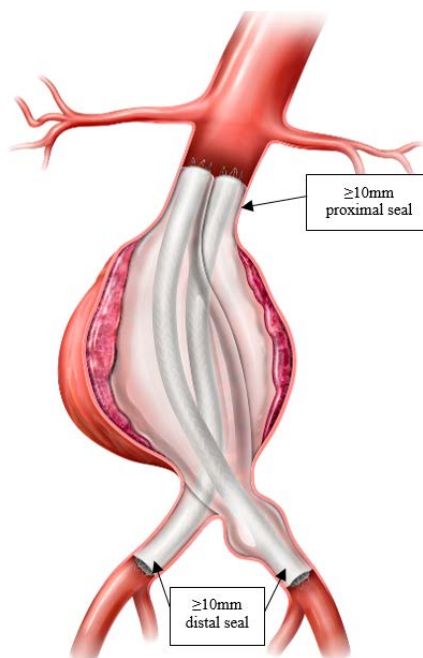
#### ***Attachment 4: Reminder of Secondary Intervention Treatment Options***

(Note: clinical evidence to support the safety of these techniques is limited)

**Endologix does not recommend or endorse use of its products other than in accordance with their indications for use. The following information is being shared in the interest of patient safety only. Endologix has limited data for uses out of the scope of the intended use. Should a physician decide to use Nellix out of the intended use in the best interest of a patient, it is critical that the physician is sufficiently informed to evaluate this option.**

#### **Treatment Options for Isolated Migration**

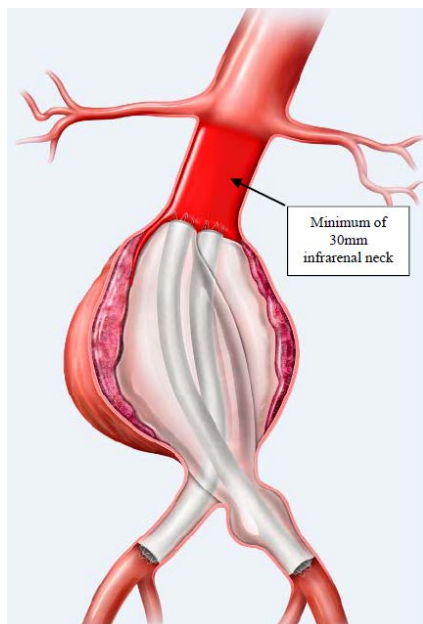
For isolated migration, when adequate proximal and distal seal is present and in the absence of endoleaks, one treatment option to consider is relining the entire length of each existing stent with an additional Nellix stent (no polymer), to provide resistance to lateral or anterior displacement. When adequate proximal and distal seal is present and the implant has migrated <10mm, Endologix recommends an option of routine surveillance utilizing either contrast or non-contrast computed tomography (CT). **Figure 13** provides an illustration of an isolated Nellix migration suitable for Nellix relining.



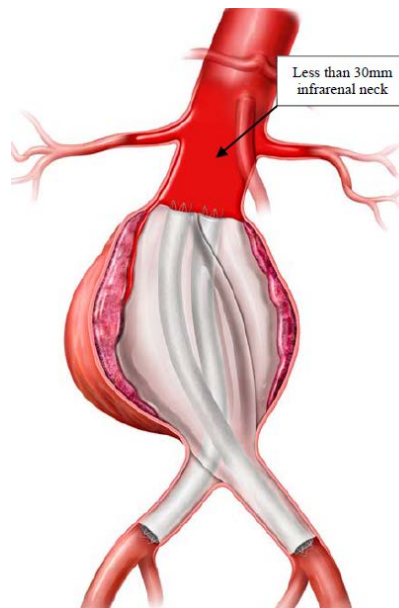
**Figure 13: Example of Nellix migration suitable for Nellix relining**

#### **Treatment Options for Migration with Associated Type Ia Endoleaks**

For subjects with migration and an associated Type Ia endoleak, options to consider include treatment with the Nellix device as a proximal extension, known as Proximal Extenders (when >30mm of infrarenal neck is available) and Proximal Extenders in conjunction with commercially available stent grafts in the visceral arteries (when <30mm of infrarenal neck is available). **Figure 14** provides an illustration of Nellix migration associated with Type Ia endoleak suitable for treatment with Nellix proximal extenders only while **Figure 15** provides an illustration of a Nellix migration associated with Type Ia endoleak, where both a Nellix proximal extender and visceral stent grafts are recommended.

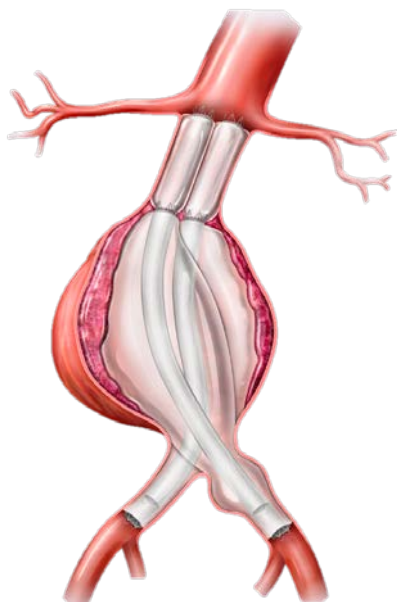


**Figure 14:** Example of migration and Type Ia endoleak suitable for Nellix proximal extenders

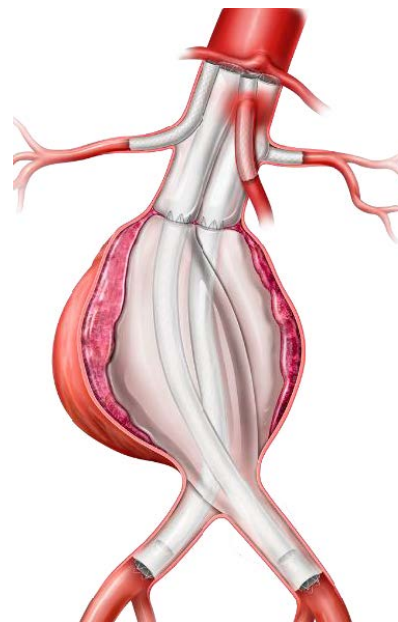


**Figure 15:** Example of migration and Type Ia endoleak suitable for Nellix proximal extenders with commercially available stent grafts in the visceral arteries

**Figure 16** provides an illustration post-treatment with Nellix proximal extenders and **Figure 17** provides an illustration post-treatment with Nellix proximal extenders with commercially available stent grafts in the visceral arteries.



**Figure 16:** Post-treatment with Nellix proximal extenders

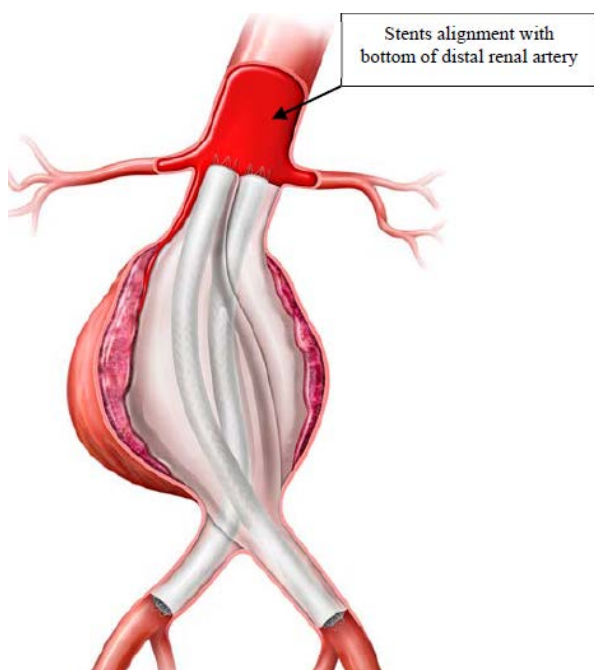


**Figure 17:** Post-treatment with Nellix proximal extenders and commercially available stent grafts in the visceral arteries

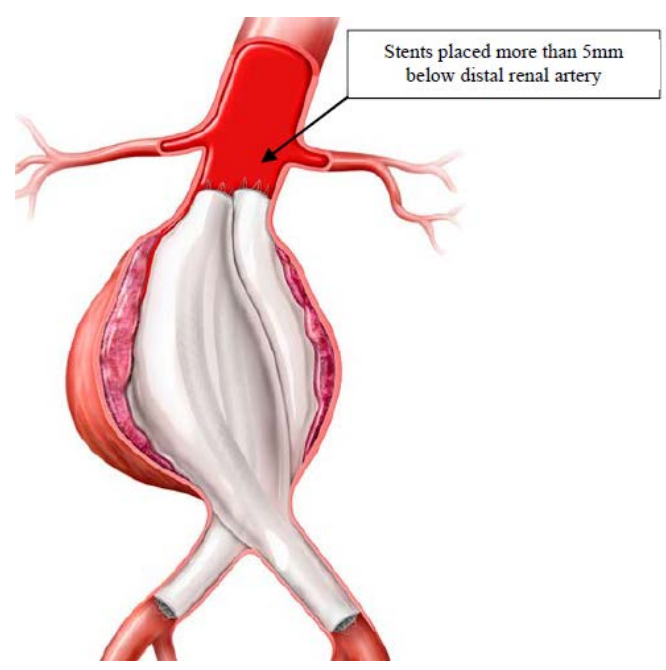


### Treatment Options for Isolated Type Ia Endoleak

For subjects with isolated Type Ia endoleak (without migration), options to consider include treatment with coils/liquid embolics if the Nellix implant is positioned correctly (i.e. bottom of the first stent cell element is aligned with the distal origin of the most caudal renal artery) and coils/liquid embolics with commercially available proximal covered stents if the Nellix implant was positioned incorrectly (i.e. too far below the renal arteries), with a proximal seal of at least 10 mm. **Figure 18** provides an illustration of a Nellix Type Ia endoleak suitable for treatment with coils and liquid embolics only as the original Nellix stents are correctly positioned. **Figure 19** provides an illustration of a Nellix Type Ia endoleak suitable for coils and liquid embolics with proximal extension due to incorrect positioning of the original Nellix stents.

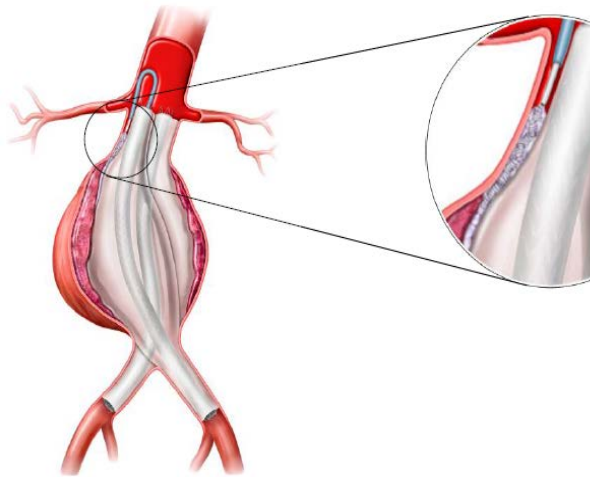


**Figure 18: Example of Nellix Type Ia endoleak suitable for treatment with coils and liquid embolics only with correct stent positioning**

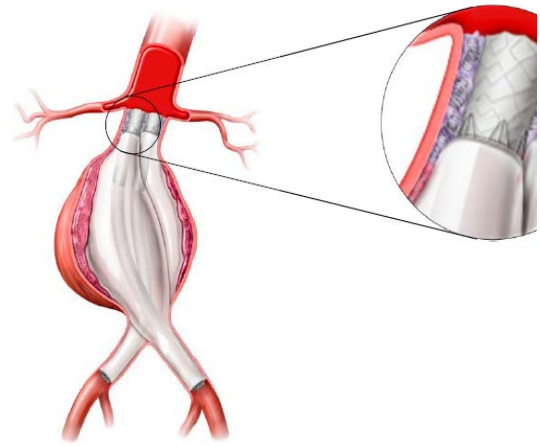


**Figure 19: Example of Nellix Type Ia endoleak suitable for coils and liquid embolics with proximal extension due to incorrect stent positioning**

**Figure 20** provides an illustration post-treatment with coils and liquid embolics only and **Figure 21** provides an illustration post-treatment with coils, liquid embolics, and proximal extenders.



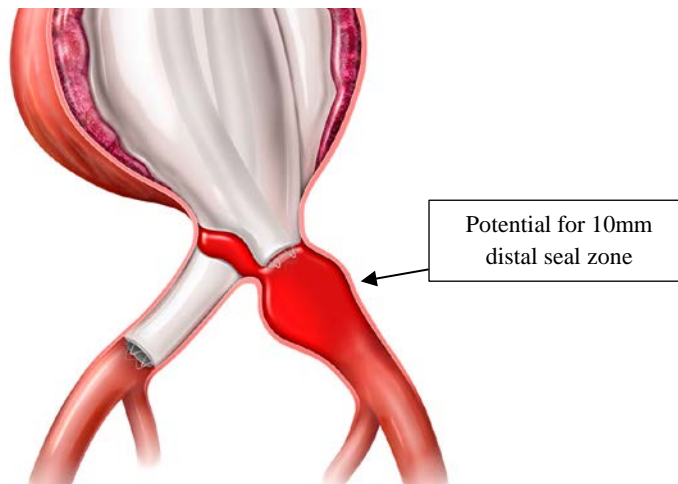
**Figure 20: Post-treatment with coils and liquid embolics only**



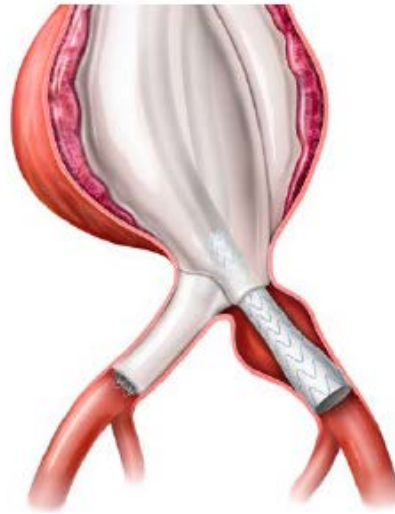
**Figure 21: Post-Treatment with coils, liquid embolics and proximal extension**

### Treatment Options for Type Ib Endoleak

For subjects with Type Ib endoleaks, a potential treatment option is use of the Ovation iX Iliac Stent Graft as a distal extender to re-establish the sealing zone. **Figure 22** provides an illustration of a Type Ib endoleak suitable for distal extension and **Figure 23** provides an illustration post-treatment with distal extenders.



**Figure 22: Example of Nellix Type Ib endoleak suitable for distal extension with the Ovation iX Iliac Stent Graft**

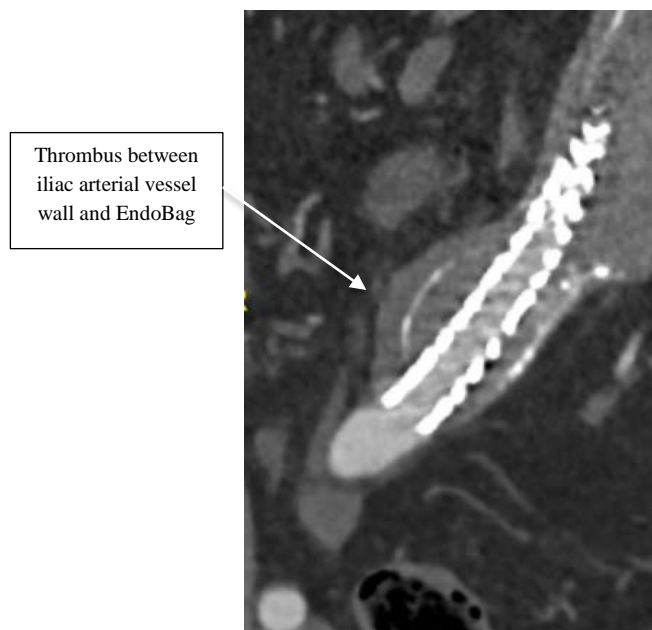


**Figure 23: Post-treatment with the Ovation iX Iliac Stent Graft distal extension**

### Treatment Options for Aneurysm Enlargement

For subjects with aneurysm enlargement, if a Type Ia/Ib endoleak is present, treatment of the endoleak as described above may also address the aneurysm enlargement.

If aneurysm enlargement occurs in the absence of a Type Ia/Ib endoleak, one option to consider is treatment with an Ovation iX Iliac Stent Graft as a distal extender, as aneurysm enlargement may occur due to lack of apposition of the EndoBag to the arterial wall which allows pressurization of the aneurysm sac. As shown in **Figure 24** below, when there is an inadequate distal seal, the aneurysm sac can be pressurized due to the thrombus between the iliac artery and the distal portion of the Nellix implant. Pressurization of the aneurysm sac results in thrombus accumulation and aneurysm enlargement. To prevent further aneurysm enlargement, the distal seal between the iliac arterial wall and the EndoBag can be re-established with distal extension using the Ovation iX Iliac Stent Graft.



**Figure 24: Image of aneurysm enlargement caused by pressurization**